




The Preventive Effect of N-Acetylcysteine on Liver Tissue Against Doxorubicin-Induced Oxidative Stress in Rats

Suat Cakina¹  • Samil Ozturk¹  • Latife Ceyda Irkin² 

¹ Çanakkale Onsekiz Mart University, Health Service Vocational College, 17100, Çanakkale, Türkiye, suatcakina@comu.edu.tr, samilozturk16@hotmail.com

² Çanakkale Onsekiz Mart University, Çanakkale Faculty of Applied Sciences, Department of Fisheries Technology, 17100, Çanakkale, Türkiye, latifeirkin@gmail.com

✉ Corresponding Author: suatcakina@comu.edu.tr

Please cite this paper as follows:

Cakina, S., Ozturk, S., & Irkin, L. C. (2024). Title: The Preventive Effect of N-Acetylcysteine on Liver Tissue Against Doxorubicin-Induced Oxidative Stress in Rats. *Acta Natura et Scientia*, 5(1), 11-18. <https://doi.org/10.61326/actanatsci.v5i1.2>

ARTICLE INFO

Article History

Received: 04.12.2023

Revised: 13.02.2024

Accepted: 05.03.2024

Available online: 22.05.2024

Keywords:

Doxorubicin

N-Acetylcysteine

Liver

Oxidative stress.

A B S T R A C T

Doxorubicin (DOX) is a chemotherapeutic agent and is widely used in cancer treatment. There are some studies suggesting oxidative stress-induced toxic changes in the liver due to DOX administration. The aim of this study was to reveal the oxidative damage of DOX in liver tissue at molecular level and to evaluate the protective effect of N-acetyl cysteine (NAC) against DOX oxidative damage. Twenty four rats weighing 150-200 g were randomly divided into four equal groups; group 1: control, group 2: received a single dose of DOX, group 3: received NAC for 28 days and group 4: received a single dose of DOX, followed by NAC for 28 days. At the end of the experiment, liver tissues were taken from all animals. Total Antioxidant Capacity (TAC), Total Oxidant Capacity (TOC) levels were determined in these samples by spectrophotometric methods. The histopathological changes of liver tissue were observed routinely in histological staining. It was determined that TOC level increased, TAC levels decreased in the group given DOX compared to the control group. In addition, TAC levels increased in the DOX+NAC group. It was showed the occurrence of congestion in portal triad, and pycnotic cells degeneration in DOX group. It was concluded that DOX administration increased oxidative stress and NAC administration could prevent the increased oxidative stress ($p < 0.05$). NAC caused modulatory effects on oxidative stress and antioxidant redox system in DOX-induced liver toxicity in the rat.

INTRODUCTION

Doxorubicin (DOX) is an anti-cancer agent used in the treatment of ovarian, breast, liver and lung cancers and solid tumors such as leukemia and lymphoma. In

cancer treatment, it is used to block cell division of tumor cells (Aljobaily et al., 2020). However, since it is a highly toxic antineoplastic agent, it causes toxicity on many organs and tissues in the organism. Studies have reported toxic effects on the heart, brain, liver,

kidney, kidney, skin and reproductive organs such as ovaries and testes. It is known that the liver is one of the most vulnerable organs to DOX damage. Although the mechanism of DOX-mediated liver injury is not fully known, it is supported that increased free radical formation and lipid peroxidation as well as decreased antioxidant enzymes may play a role (Moslehi, 2016; Timm et al., 2021; Yu et al., 2020).

Due to its toxicity on organs, studies are carried out with many agents that will eliminate or minimize this effect. One of these is N-acetylcysteine (NAC). NAC is a mucolytic agent that plays a role in the formation of glutathione, an effective antioxidant. NAC has a protective effect against tissue damage caused by free radicals (Saricaoglu et al., 2005; Arakawa & Ito, 2007; Koçkar et al., 2010).

Lipid peroxidation is the reaction in which fatty acids in the membrane are destroyed by free oxygen radicals. Malondialdehyde (MDA), which can be measured with thiobarbituric acid, is formed in the peroxidation of fatty acids formed by the destruction of lipid hydroperoxides. This method is a frequently preferred method for measuring lipid peroxide levels. Lipid peroxidation plays an important role in disease pathogenesis by inducing changes that lead to cell damage (Hjelle & Petersen, 1983; Saleh et al., 2022).

The aim of this study was to reveal the oxidative damage of DOX in liver tissue at molecular level and to evaluate the protective effect of NAC against the oxidative damage of DOX on this tissue.

MATERIAL AND METHODS

Adult male Wistar Albino rats obtained from Çanakkale Onsekiz Mart University Experimental Research and Application Center were used in this study. Animals were maintained under standard environmental conditions and had free access to standard rodent feed and water. Our work was carried out in accordance with the guidelines of the Ethical Committee of Çanakkale Onsekiz Mart University Faculty of Medicine approved the current study (Ethics number: 2022-2200189432). Experiments were conducted in accordance with international guidelines for the ethical use of rats.

Rats were randomly divided in to four experimental groups (6 rats per group) as follows:

- Group 1: Control
- Group 2: DOX (20 mg/kg, intraperitoneal)
- Group 3: NAC (50 mg/kg/day, via gavage) for 28 days
- Group 4: DOX (20 mg/kg Doxorubicin, intraperitoneal) + NAC (50 mg/kg/day, via gavage) for 28 days (from the day of DOX administration)

At the end of the experimental period, the rats were anesthetized by ketamine and xylazine hydrochloride. Then, liver was moved for measuring the oxidative stress markers the rats.

Tissue samples were homogenized in phosphate buffer solution (1:10 w/v, pH: 7.4) using ice-cooled tubes. The homogenate was centrifuged (14,000 rpm, 30 min) and the supernatants were separated for analysis. Protein concentration was estimated by the method of Lowry et al. (1951). Tissue samples, taken for malondialdehyde determination, were homogenized and subjected to procedures as outlined before (Ohkawa et al., 1979). TAC and TOC levels were measured by a spectrophotometric assay using commercially available kits (Rel Assay Diagnostics, Turkey). The OSI was defined as the ratio of the TAC level to TOC level.

Liver tissues fixed with 10% buffered formaldehyde were subjected to routine histologic follow-up. The tissues were embedded in paraffin and then 4 micrometer sections were taken from the blocks with a sliding-microtome and deparaffinized. Rehydrated sections were stained with Mayer hematoxylin and eosin stains. After the procedure, the sections were covered with entellan and evaluated histopathologically under light microscope. Liver histopathologic evaluations were performed according to Gibson-Corley et al. (2013). In the scoring process performed in 10 random fields in the micrographs at 200× magnification obtained from random sections taken from all samples of each group, 0 was determined as none, 1 as mild, 2 as extensive and 3 as severe (Gibson-Corley et al., 2013). In pyknotic nuclei counting performed in liver tissues,

pyknotic nuclei detected in 5 random fields of random sections were counted with the help of ImageJ (NIH, USA, Version 1.53J) program.

Statistical Analysis

Statistical software (IBM SPSS version 19.0, USA) was used to analyze the data obtained. Comparison of multiple groups was determined by analysis of variance (one-way ANOVA) with post hoc Duncan test. Differences were considered significant at $P < 0.05$. All variables were represented as mean \pm standard error of the mean (SE).

RESULTS

In group 2 given DOX and group 4 given DOX+NAC; TAC levels decreased compared to the control group (respectively $p=0.14$; $p < 0.001$) (Table 1 and Figure 1).

Table 1. TAC analysis results

Group	TAC (mmole/L)	P Value
Control	2.16 \pm 0.87	
DOX	1.61 \pm 0.37	§p:0.14
NAC	2.09 \pm 0.07	
DOX+NAC	1.90 \pm 0.05	‡p:<0.001

Note: Group comparisons: §p=group 1 and group 2; ¶p=group 1 and group 3; ‡p=group 1 and group 4; #p=group 2 and group 4.

Table 2. TOC analysis results

Group	TOC (μ mole/L)	P Value
Control	24.58 \pm 5.68	
DOX	36.65 \pm 2.36	§p:0.002
NAC	23.78 \pm 1.39	
DOX+NAC	23.40 \pm 4.12	#p:<0.001

Note: Comparisons: §p=group 1 and group 2; ¶p=group 1 and group 3; ‡p=group 1 and group 4; #p=group 2 and group 4.

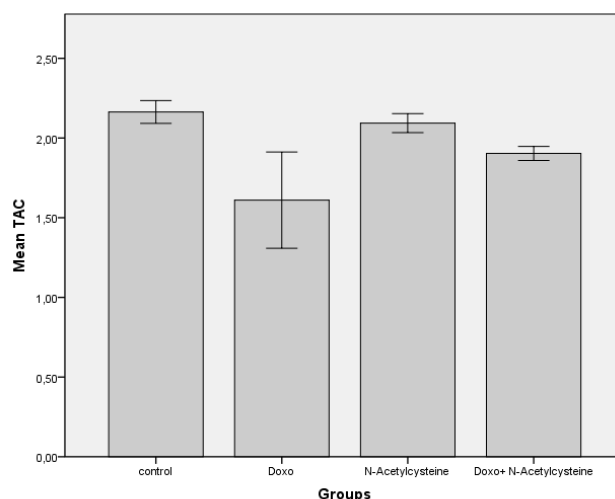


Figure 1. Groups-TAC results

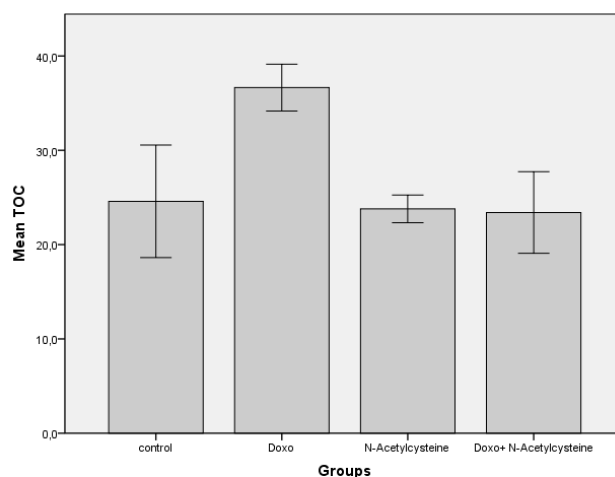


Figure 2. Groups-TOC results

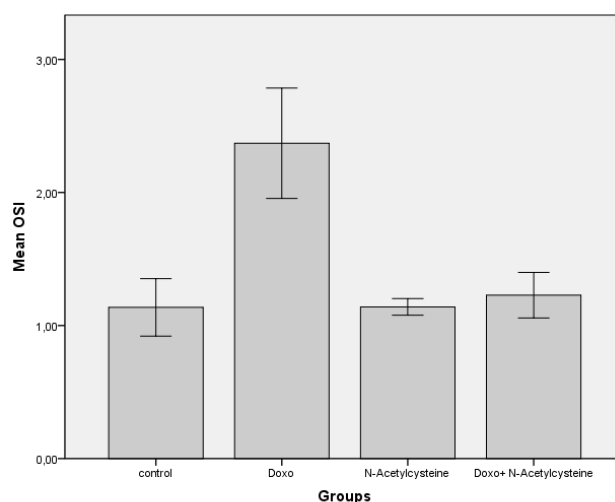


Figure 3. Groups-OSI results

Table 3. OSI analysis results

Group	OSI ratio	P Value
Control	1.14±0.26	
DOX	2.37±0.50	§p:0.001
NAC	1.14±0.07	
DOX+NAC	1.22±0.21	#p:<0.002

Note: $OSI = \frac{TOC (\mu\text{mole } H_2O_2 \text{ Equiv./gram protein})}{TAC (\mu\text{mole } H_2O_2 \text{ Equiv./gram protein})} \times 100$

Group Comparisons: §p=group 1 and group 2; ¶p=group 1 and group 3; ‡p=group 1 and group 4; #p=group 2 and group 4.

In group 2 given DOX, TAC levels increased compared to the control group (p=0.002). In group 4 given DOX+NAC, TAC levels decreased compared to the group 2 given DOX (p<0.001) (Table 2 and Figure 2).

In group 2 given DOX, OSI ratio increased compared to the control group (p=0.001). In group 4

given DOX+NAC, OSI ratio decreased compared to the group 2 given DOX (p<0.002) (Table 3 and Figure 3).

Inflammatory cell infiltration showing intergroup comparisons was commonly observed in DOX type stroma, while almost none was observed in control types. Congestion and hemorrhagic areas were observed in all groups except the control group (Figure 4A.). Especially hemorrhagic areas were frequently observed in the DOX group. Hemorrhage was observed in the DOX group both in and around the vessel lumen (Figure 4B). Hepatosteatosi and high amounts were scored in DOX and DOX+NAC groups. Steatosis was mostly observed in the connections close to the hepatic triad. The highest amount of pyknotic nuclei was again observed in DOX class, while DOX+NAC class showed loss (Table 4 and Figure 4)

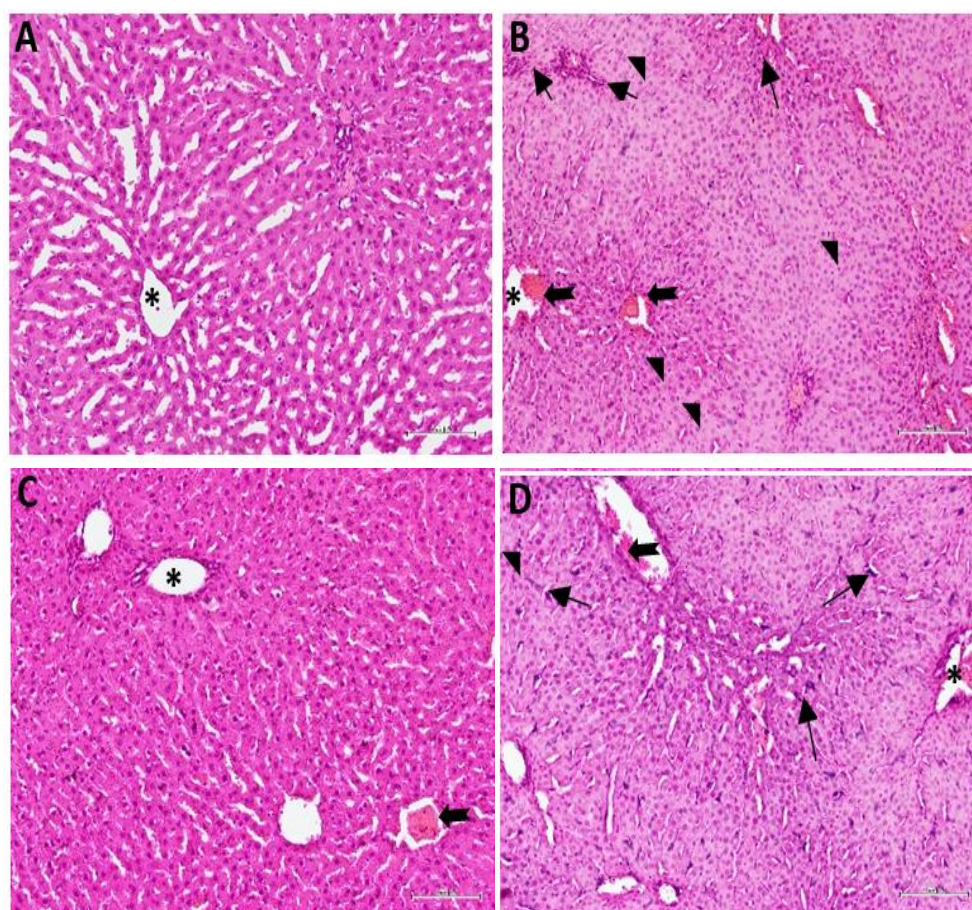


Figure 4. Liver section micrographs of the groups with H-E staining applied (These are micrographs belonging to the groups A: control, B: DOX, C: Nac, D: DOX+Nac. (It belongs to 200× magnification). Asterix indicates central vein, arrowhead indicates steatosis, thick arrows indicate congestion and hemorrhages, and thin arrows indicate inflammatory cell areas)

Table 4. Effects of NAC on some pathological changes in liver tissue of DOX -treated rats

Group	Inflammatory cell infiltration	Number of pyknotic nuclei	Hepatosteatosis	Hemorrhage
Control	0.20±0.08	1.93±0.02	0.20±0.07	0.10±0.04
DOX	2.57±0.02 ^{SP}	10.13±0.62 ^{SP}	2.53±0.02 ^{SP}	2.07±0.02 ^{SP}
NAC	1.17±0.01 ^{1P}	2.53±0.27	0.70±0.02 ^{1P}	1.26±0.01 ^{1P}
DOX +NAC	1.80±0.09 ^{1P}	6.46±0.07 ^{1P, #P}	1.80±0.17 ^{1P, #P}	1.86±0.02 ^{1P, #P}

Note: Group Comparisons: ^{SP}=group 1 and group 2; ^{1P}=group 1 and group 3; ^{1P}=group 1 and group 4; ^{#P}=group 2 and group 4.

DISCUSSION

DOX is widely used in the treatment of various malignant diseases, including breast, ovarian, testicular, thyroid, lung and hematologic cancers. However, its use is limited due to its cytotoxic effect on both normal and cancerous cells (Alshabanah et al., 2010; Gibson-Corley et al., 2013; Biller, 2014; Rivankar, 2014). Bilgic & Ozgocmen (2019) showed that single dose doxorubicin administration may cause acute liver injury. In our study, we found that although liver TAC concentrations decreased with DOX administration, TOC levels increased. Therefore, DOX administration in animals is characterized by increased TOC levels and decreased TAC concentrations. Furthermore, liver TOC levels decreased with NAC treatment, but TAC concentrations increased with NAC treatment. Numerous in vivo or in vitro studies on the effects of NAC on the level of oxidative stress have been reported (Saricaoglu et al., 2005; Samuni et al., 2013; Otrubová et al., 2018). To our knowledge, this is the first study to investigate the effects of NAC on the antioxidant system in DOX -induced hepatotoxicity in rats. Our results are consistent with the results of previous studies regarding the increase in oxidative stress in the liver after DOX treatment.

Prasanna et al. (2020) concluded that oxidative stress is the primary cause of DOX -induced liver injury. As a result of DOX-induced oxidative stress, electrons are lost from oxygen, leading to the production of superoxide radicals and reactive oxygen species (ROS). High levels of ROS also lead to an increase in lipid peroxidation. This results in damage to hepatocytes and liver. In our study, it was

found that DOX+NAC group increased TAC levels and decreased TOC levels compared to DOX group. Studies have shown that NAC increases intracellular GSH, which directly scavenges oxidants and protects against ROS-related oxidative stress.

In various studies, NAC supplementation was found to reduce increased MDA levels in rat liver. In a similar study, it was reported that expressed as Glutathione Peroxidase (GSH-Px) activity did not change in the liver of DOX+NAC-treated rats, thus liver cell damage was less. NAC is both a potent antioxidant and a precursor of reduced glutathione (GSH) (Saricaoglu et al., 2005; Arakawa & Ito, 2007; Koçkar et al., 2010; Samuni et al., 2013).

Histologic evaluation showed that TAC levels and tissue degeneration decreased with NAC administration. NAC shows antioxidant properties. However, NAC reacts weakly with hydrogen peroxide and superoxide radicals. As a result of our study, we observed the protective effect of NAC on liver antioxidant/oxidant after DOX -induced liver injury. It can be said that NAC plays an active role in reducing superoxide anion and hydroxyl radical release and shows antioxidant properties. We did not examine liver GSH-Px activity in this study because NAC reacts poorly with hydrogen peroxide. However, in this study, liver GSH levels increased with NAC administration because NAC facilitates GSH biosynthesis (Saricaoglu et al., 2005; Bulucu et al., 2009; Koçkar et al., 2010; Li et al., 2016). Similarly, Bulucu et al. (2009) observed that GSH-Px activity was not altered in the liver of rats by DOX and NAC administration. Nagasaki et al. (1998) showed that in a GSH-depleted liver, NAC prevented hepatic injury and improved liver integrity after

ischemia/reperfusion injury by acting directly as a free radical scavenger and not as a substrate for GSH synthesis.

As a result of the examination of liver tissues removed from the subjects in our study, mononuclear cell infiltration, hyperchromatic nuclei in hepatocytes, dilatation in sinusoids and vacuolar degeneration were reported as important structural changes in the DOX group. In many previous studies conducted with DOX, it was determined that the histopathological changes occurring in the liver tissue were structural changes similar to the findings of our study (El-Sayyad et al., 2009; Bilgic & Ozgocmen, 2019; Sikandar et al., 2020).

When we compared the liver tissue of the DOX+NAC group with the group administered DOX alone, a significant decrease in sinusoidal dilatation, inflammation and pyknotic cells was noted. It has been reported that NAC application has beneficial effects similar to these findings in different hepatotoxicity models (Otrubová et al., 2018). The underlying role of NAC in these effects is still debated because its molecular mechanisms are quite complex (Samuni et al., 2013). There are different theories that partially explain the effects of NAC. One of these is the generally accepted classification that it is one of the 'good' antioxidants. Another is that it is associated with 'bad' antioxidants. Its effects on tumor cells are similarly controversial. It was reported by Li et al. (2016), that NAC showed quite opposite effects in tumor cells. They reported that NAC protects telomerase activity in normal cells but inhibits it in cancer cells. Researchers have linked this to opposing effects on telomerase activity. We hypothesize that this situation is due to different intracellular redox homeostasis in normal and tumor cells.

Many *in vivo* and *in vitro* studies have reported that DOX promotes cell death in various tissues by increasing oxidative stress (Yu et al., 2020; Zhang et al., 2020). We also found that DOX significantly increased TAC and TOC in liver tissue and increased the apoptotic index. In the DOX+NAC group, TOC and apoptotic index were found to be significantly reduced in treated animals. Similar to our results, they reported that apoptosis and liver damage decreased

after NAC application in the CCl₄-induced liver injury model (Otrubová et al., 2018)

CONCLUSION

As a result, NAC shows modulatory effects on oxidative stress and antioxidant redox system in Doxorubicin-induced liver toxicity in the rat. More extensive studies are needed on this subject.

ACKNOWLEDGEMENTS

This work was supported by Çanakkale Onsekiz Mart University, Scientific Research Unit (TSA-2022-4230).

Compliance with Ethical Standards

Authors' Contributions

SC: Conceptualization, Writing – Original draft, Data curation, Formal analysis, Writing – review & editing

SO: Conceptualization, Writing – Original draft, Data curation, Formal analysis

LCI: Conceptualization, Writing – Original draft, Data curation, Formal analysis

All authors read and approved the final manuscript.

Conflict of Interest

The authors declare that there is no conflict of interest.

Ethical Approval

Ethical Committee of Çanakkale Onsekiz Mart University Faculty of Medicine approved the study (Ethics number: 2022-2200189432). All applicable international, national, and/or institutional guidelines for the care and use of animals were followed.

Funding

This work was supported by Çanakkale Onsekiz Mart University, Scientific Research Unit (TSA-2022-4230).

Data Availability

The data that support the findings of this study are available from the corresponding author upon request.

REFERENCES

- Aljobaily, N., Viereckl, M. J., Hydock, D. S., Aljobaily, H., Wu, T.-Y., Busekrus, R., & Han, Y. (2020). Creatine alleviates doxorubicin-induced liver damage by inhibiting liver fibrosis, inflammation, oxidative stress, and cellular senescence. *Nutrients*, 13(1), 41. <https://doi.org/10.3390/nu13010041>
- Alshabanah, O. A., Hafez, M. M., Al-Harbi, M. M., Hassan, Z. K., Al Rejaie, S. S., Asiri, Y. A., & Sayed-Ahmed, M. M. (2010). Doxorubicin toxicity can be ameliorated during antioxidant L-carnitine supplementation. *Oxidative Medicine and Cellular Longevity*, 3(6), 428-433. <https://doi.org/10.4161/oxim.3.6.14416>
- Arakawa, M., & Ito, Y. (2007). N-acetylcysteine and neurodegenerative diseases: basic and clinical pharmacology. *Cerebellum*, 6(4), 308-314. <https://doi.org/10.1080/14734220601142878>
- Bilgic, S., & Ozgocmen, M. (2019). The protective effect of misoprostol against doxorubicin induced liver injury. *Biotechnic & Histochemistry*, 94(8), 583-591. <https://doi.org/10.1080/10520295.2019.1605457>
- Billir, B. (2014). Metronomic chemotherapy in veterinary patients with cancer: rethinking the targets and strategies of chemotherapy. *The Veterinary Clinics of North America. Small Animal Practice*, 44(5), 817-829. <https://doi.org/10.1016/j.cvsm.2014.05.003>
- Bulucu, F., Ocal, R., Karadurmus, N., Sahin, M., Kenar, L., Aydin, A., & Yaman, H. (2009). Effects of N-acetylcysteine, deferoxamine and selenium on doxorubicin-induced hepatotoxicity. *Biological Trace Element Research*, 132(1-3), 184-196. <https://doi.org/10.1007/s12011-009-8377-y>
- El-Sayyad, H. I., Ismail, M. F., Shalaby, F. M., Abou-El-Magd, R. F., Gaur, R. L., Fernando, A., Raj, M. H. G., & Ouhtit, A. (2009). Histopathological effects of cisplatin, doxorubicin and 5-fluorouracil (5-FU) on the liver of male albino rats. *International Journal of Biological Sciences*, 5(5), 466-473. <https://doi.org/10.7150/ijbs.5.466>
- Gibson-Corley, K. N., Olivier, A. K., & Meyerholz, D. K. (2013). Principles for valid histopathologic scoring in research. *Veterinary Pathology*, 50(6), 1007-1015. <https://doi.org/10.1177/0300985813485099>
- Hjelle, J. J., & Petersen, D. R. (1983). Metabolism of malondialdehyde by rat liver aldehyde dehydrogenase. *Toxicology and Applied Pharmacology*, 70(1), 57-66. [https://doi.org/10.1016/0041-008X\(83\)90179-5](https://doi.org/10.1016/0041-008X(83)90179-5)
- Koçkar, M. C., Nazıroğlu, M., Çelik, Ö., Tola, H. T., Bayram, D., & Koyu, A. (2010). N-acetylcysteine modulates doxorubicin-induced oxidative stress and antioxidant vitamin concentrations in liver of rats. *Cell Biochemistry and Function*, 28(8), 673-677. <https://doi.org/10.1002/cbf.1707>
- Li, P., Wu, M., Wang, J., Sui, Y., Liu, S., & Shi, D. (2016). NAC selectively inhibit cancer telomerase activity: A higher redox homeostasis threshold exists in cancer cells. *Redox Biology*, 8, 91-97. <https://doi.org/10.1016/j.redox.2015.12.001>
- Lowry, O. H., Rosebrough, N. J., Farr, A. L., & Randall, R. J. (1951). Protein measurement with the Folin phenol reagent. *Journal of Biological Chemistry*, 193(1), 265-275. [https://doi.org/10.1016/S0021-9258\(19\)52451-6](https://doi.org/10.1016/S0021-9258(19)52451-6)
- Moslehi, J. J. (2016). Cardiovascular toxic effects of targeted cancer therapies. *The New England Journal of Medicine*, 375(15), 1457-1467. <https://doi.org/10.1056/nejmra1100265>
- Nagasaki, H., Nakano, H., Boudjema, K., Jaeck, D., Alexandre, E., Baek, Y., Kitamura, N., Yamaguchi, M., & Kumada, K. (1998). Efficacy of preconditioning with N-acetylcysteine against reperfusion injury after prolonged cold ischaemia in rats liver in which glutathione had been reduced by buthionine sulphoximine. *European Journal of Surgery*, 164(2), 139-146. <https://doi.org/10.1080/110241598750004805>
- Ohkawa, H., Ohishi, N., & Yagi, K. (1979). Assay for lipid peroxides in animal tissues by thiobarbituric acid reaction. *Analytical Biochemistry*, 95(2), 351-358. [https://doi.org/10.1016/0003-2697\(79\)90738-3](https://doi.org/10.1016/0003-2697(79)90738-3)

- Otrubová, O., Turecký, L., Uličná, O., Janega, P., Luha, J., & Muchová, J. (2018). Therapeutic effects of N-acetyl-L-cysteine on liver damage induced by long-term CCl₄ administration. *General Physiology and Biophysics*, 37(1), 23-31. https://doi.org/10.4149/gpb_2017016
- Prasanna, P. L., Renu, K., & Gopalakrishnan, A. V. (2020). New molecular and biochemical insights of doxorubicin-induced hepatotoxicity. *Life Sciences*, 250, 117599. <https://doi.org/10.1016/j.lfs.2020.117599>
- Rivankar, S. (2014). An overview of doxorubicin formulations in cancer therapy. *Journal of Cancer Research and Therapeutics*, 10(4), 853–858. <https://doi.org/10.4103/0973-1482.139267>
- Saleh, D. O., Mahmoud, S. S., Hassan, A., & Sanad, E. F. (2022). Doxorubicin-induced hepatic toxicity in rats: Mechanistic protective role of Omega-3 fatty acids through Nrf2/HO-1 activation and PI3K/Akt/GSK-3 β axis modulation. *Saudi Journal of Biological Sciences*, 29(7), 103308. <https://doi.org/10.1016/j.sjbs.2022.103308>
- Samuni, Y., Goldstein, S., Dean, O. M., & Berk, M. (2013). The chemistry and biological activities of N-acetylcysteine. *Biochimica et Biophysica Acta*, 1830(8), 4117–4129. <https://doi.org/10.1016/j.bbagen.2013.04.016>
- Saricaoglu, F., Dal, D., Salman, A. E., Atay, O. A., Doral, M. N., Salman, M. A., Kilinç, K., & Aypar, U. (2005). Effect of low-dose N-acetyl-cysteine infusion on tourniquet-induced ischaemia-reperfusion injury in arthroscopic knee surgery. *Acta Anaesthesiologica Scandinavica*, 49(6), 847-851. <https://doi.org/10.1111/j.1399-6576.2005.00722.x>
- Sikandar, A., Farhat, K., Afzal, A., Ajmal, K., Laeeq, M., & Khokhar, A. (2020). Protective effects of trimetazidine against doxorubicin-induced cardiotoxicity and hepatotoxicity in mice. *Journal of Ayub Medical College, Abbottabad: JAMC*, 32(3), 304-309.
- Timm, K. N., Ball, V., Miller, J. J., Savic, D., West, J. A., Griffin, J. L., & Tyler, D. J. (2021). Metabolic effects of doxorubicin on the rat liver assessed with hyperpolarized MRI and metabolomics. *Frontiers in Physiology*, 12, 782745. <https://doi.org/10.3389/fphys.2021.782745>
- Yu, X., Ruan, Y., Huang, X., Dou, L., Lan, M., Cui, J., & Shen, T. (2020). Dexrazoxane ameliorates doxorubicin-induced cardiotoxicity by inhibiting both apoptosis and necroptosis in cardiomyocytes. *Biochemical and Biophysical Research Communications*, 523(1), 140–146. <https://doi.org/10.1016/j.bbrc.2019.12.027>
- Zhang, J., Wang, M., Ding, W., Zhao, M., Ye, J., Xu, Y., Wang, Z., Ye, D., Li, D., Liu, J., & Wan, J. (2020). Resolvin E1 protects against doxorubicin-induced cardiotoxicity by inhibiting oxidative stress, autophagy and apoptosis by targeting AKT/mTOR signaling. *Biochemical Pharmacology*, 180, 114188. <https://doi.org/10.1016/j.bcp.2020.114188>